

**A Case Review**

## **Spontaneous Resolution of a Traumatic Cataract in Cerebral Palsy Libyan Patient**

**khalid A.k Elmajri<sup>1\*</sup> and Khalifa Alsuidi<sup>2</sup>**

<sup>1</sup>Ophthalmology Department , Faculty of Medicine , Derna University , Derna, Libya

<sup>2</sup> Ophthalmology Department, Faculty of Medicine , University of Tripoli, Tripoli, Libya

Corresponding Author\*: Dr. Khalid A. K. Elmajri, Ophthalmology Department , Faculty of Medicine , Derna University , Derna, Libya. Email: [Asdderna@yahoo.com](mailto:Asdderna@yahoo.com)

**Received:** 25 April 2023

**Accepted:** 28 May 2023

**Published:** 20 June 2023

### **ABSTRACT:**

An 10-year-old boy came as emergency case to ophthalmology clinic in a teaching Alwahda Derna hospital with trauma right eye by spoon food accidentally by his sister for evaluation of a possible open globe and management. The boy complained of pain, was taken to the local emergency treatment center for evaluation. A slit lamp examination failed to reveal a foreign body. Early the next morning he awoke with worsening pain. On examination by ophthalmologist noted a small corneal laceration 2 to 3 mm at 8 to 9 - O clock and lenticular change (cataract). Results show no prior ocular injury, surgery, or illness. Also, patient was with known case of cerebral palsy. The spontaneous resolution occurred through 6 months. Treatment of pediatric traumatic cataract and conservative management with lens preservation is important for young traumatic cataract patients rather than invasive surgical intervention.

**KEYWORDS:** Ophthalmology Clinic, Trauma Right Eye, Cerebral Palsy.



## **INTRODUCTION**

The rate of surgery in eastern Mediterranean countries remains low. The provision of widespread cataract surgery delivered in a timely fashion before individuals are visually impaired by this condition may result for a reduction of blindness and visual loss.

A related disturbing issue is the frequency with which ophthalmic surgery results in intra operative or postoperative complications.

In several eastern Mediterranean countries, the rate of complications following cataract surgery remains high. The recent introduction of new techniques for cataract surgery, including phacoemulsification, has been started by ophthalmologists in eastern Mediterranean countries.

Despite these advances, less than 20% of the cataract surgery in eastern Mediterranean countries is phacoemulsification. This is because of lack of corneal scars, and advanced mature cataracts (Ayed et al., 1991).

### ***History***

An 10-year-old male arrived as an emergency case to ophthalmology clinic in a teaching Alwahda Derna hospital. Patient diagnosed with trauma right eye because of spoon food accidentally by his sister. Patient came to ophthalmology clinic for evaluation of a possible open globe and management.

The boy complained of pain, was taken to the local emergency treatment center for evaluation. A slit lamp examination failed to reveal a foreign body.

Early the next morning he awoke with worsening pain. On examination by ophthalmologist noted a small corneal

laceration 2 to 3 mm at 8 to 9 - O clock and lenticular change (cataract).

### ***Past Ocular History:***

No prior ocular injury, surgery, or illness.

***Past Medical History:*** known case of cerebral palsy.

***Medications:*** \*Tobradex ophthalmic drops, 4x/day, in the right eye.

\*Tobradex eye ointment, twice daily

\*Pilocarpin eye drops, three times daily.

Although the incision was small but taken this decision to prevent iris prolapse through the incision.

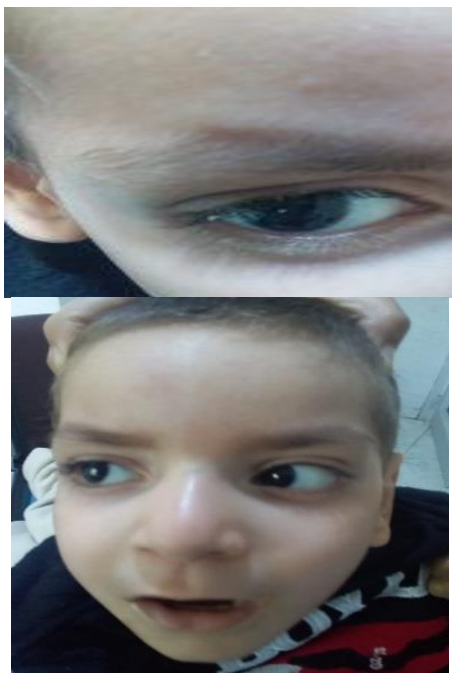
\*Vegamox eye drops , five times daily

### ***Family and Social History***

Noncontributory.

### ***Exam, Ocular:***

- Motility: Normal; no restrictions.
- Slit lamp examination:
  - 2.5 mm diameter full- thickness stellate corneal laceration (Seidel negative).
  - Anterior chamber - deep .
  - Anterior capsular no tear .
  - Posterior rosette-shaped subcapsular cataract .
- Dilated fundus exam (DFE): was difficult because cataracts changes of the lens.
- Ultrasound No foreign body. No vitreous hemorrhage, the posterior lens capsule appeared to be intact.




**Figure 1:** Cataract Change at the Time of Trauma

Follow up after three days, a rosette-shaped PCC was observed while the anterior capsule and lens nucleus were still same picture and the small corneal lacerated wound healed and pilocarpin stopped. The lens of the left eye was normal. Within another 3 days, The PCC increased in density and covered the whole pupillary area. Fundoscopic examination of the right eye were difficult to perform secondary to the cataract, however, no gross abnormalities were noted.

The Options for the management of the cataract, including cataract surgery, were discussed with the patient's father. Considering his age and his general condition, We agreed upon conservative observation. The patient returned for follow-up every 3 week, and waited for an appropriate time for surgery. At the two-month follow-up, we observed that the size of the PCC began to decrease. Five months later, only a faint imprint of the original cataract remained.

Based on the patient's age and special his satiation and difficulty to surgical intervention, The patient received conservative management and follow-up. Interestingly, Surprisingly, The cataract gradually spontaneously resolved with time over the following 5 months and the fundus appear clear and restored red reflex.



**Figure 2:** Complete Resolution of Cataract after 6 Months

## DISCUSSION

Although in traumatic cataract, cataract extraction, usually in combination with intraocular lens implantation, is required for vision correction. (Singh et. al., 2018; Du et. al., 2018). Spontaneous resolution of posterior cortical cataract (PCC) has been reported previously in cases where the cataract is caused by uncontrolled acute hyperglycemia (Ramkumar & Basti., 2008) In the case of traumatic cataracts, spontaneous reversal of PCC mainly occurs with mild or limited ocular injury, such as mild blunt contusion or small intralenticular foreign body (Avasthy & Gupta, 1958; Rofagha et. al.,2008) or transient feathering of the lens after intraocular gas tamponade (Petermeier et. al., 2010). In severe open-globe ocular injury cases, spontaneous resolution of extensive dense PCC is rare (Morschi et al., 2013).

However, if the lenticular capsule damage is limited, the proliferative lens epithelium can reseal the wound without progressive cataract formation, and in rare cases, allow cataract resolution (Rofagha et. al., 2008). The lens epithelium and fiber cells become damaged

during injury, disrupting the integrity and permeability of the lenticular capsule. This leads to an influx of aqueous humor into the lens lamella, causing it to swell and irreversibly opacify secondary to the denaturation of lens proteins (Shah et. al., 2011) Rapidly developing traumatic cataract is a common manifestation in ocular injury cases, such as intra lenticular foreign body, contusive injury and open-globe ocular injury. Brini A. et al. inferred that the resorption of small superficial lens opacities may occur in a pseudo-lysosomal fashion (Brini al., 1963). Neumayer T. et al. observed the changes and disappearance of lens vacuoles within 4 weeks in PCC patients, which might partially explain PCC spontaneous regression (Neumayer et. al., 2017).

Paradoxically, in our case, cataract density was worst at the posterior cortex and not the anterior part of lens. Previous reports indicate that in blunt ocular trauma, posterior capsular rupture is more likely to appear in children and young adults (Matalialik et. al., 2015; Bansal, & Fenerty, 2020). Wolter proposed that the absence of a sclerotic nucleus and strong zonular fibers in children and teenagers may allow the force of impact to transmit to the posterior part of lens (Lee & Song, 2001). In open-globe injury cases, cataract formation results from direct impact, and the location of the most dense opacity commonly indicates the point of greatest impact (Neumayer et al., 2017; Du et. al., 2018 ). We hypothesize that in this open-globe injury case, the PCC is secondary to indirect shock waves stemming from impact.

In young cataract patients, treatment options are more debated and require further consideration. It is known that the critical period of eye development ranges from 2 to 6 months of age, and emmetropization is generally achieved by 9 years of age (Wolter, 1963). To avoid the amblyopia, some

ophthalmologists recommend early surgical intervention for pediatric ocular traumatic cataracts, and in simple PCC cases without corneal or retinal injury, cataract extraction with intraocular lens implantation can restore excellent visual acuity (Khokhar et. al., 2017; Singh et. al., 2018.). However, in young patients, cataract extraction also results in the loss of accommodation. For children, loss of accommodation and physiologic hyperopic reserve might affect the progress of emmetropization (Medina, 2018) For teenagers, this loss of accommodation aggravates asthenopia during near work in daily life.

Trauma is a cause of monocular blindness in the developed world, although few studies have addressed the problem of trauma in rural areas. The etiology of ocular injury in rural areas is likely to differ from that in urban areas and is worthy of investigation.<sup>18</sup> . Any strategy for prevention requires knowledge of the cause of injury, which may enable more appropriate targeting of resources towards preventing such injuries. Eye trauma represents a large, potentially preventable burden on both victims and society as a whole.<sup>19</sup> importantly; conservative observation may greatly benefit the young patient by avoiding unnecessary invasive surgical intervention, and its complication and subsequent loss of vision.

## CONCLUSION

several critical factors taken in consideration when treatment traumatic cataract in pediatric such as :general condition of patient, age, the availability and extent of the possibility of performing the operation, visual development and the preservation of accommodative potential and type and extend of trauma.

Also, to optimize treatment in pediatric traumatic cataract, conservative management with lens preservation is important to consider

in young, traumatic cataract patients where invasive surgical intervention may not be required.

## REFERENCES

- Ayed, S., Daghfous, F. & Guermazi, K. 1991. Causes of blindness in Tunisian children. *Rev Int Trach Pathol Ocul Trop Subtrop Sante Publique*, **68**:123-128.
- Singh, R. B.; Thakur, S. & Ichhpujani, P. 2018. Traumatic rosette cataract. *BMJ Case Rep.*, **1** ( 1 ) : e 2 2 7 4 6 5 .
- Du, Y. He W.; Sun, X.; Lu, Y. & Zhu, X. 2018. Traumatic cataract in children in eastern China: Shanghai pediatric cataract study. *Sci Rep.*; **8** ( 1 ) : 2 5 8 8 .
- Ramkumar, H. & Basti, S. 2008. Reversal of bilateral rosette cataracts with glycemic control. *Scientific World Journal*, **8** : 1 1 5 0
- Rofagha, S.; Day, S.; Winn, B. J.; Ou, J. I.; Bhisitkul, R. B. & Chiu, C. S. 2008. Spontaneous resolution of a traumatic cataract caused by an intralenticular foreign body. *J. Cataract Refract Surg.*, **34** ( 6 ) : 1 0 3 3 - 5 .
- Avasthy, P. & Gupta, R. B. 1958. Traumatic cataract. *Br J Ophthalmol.* **42**(4):240-1.
- Petermeier, K.; Szurman, P.; Bartz-Schmidt, U. K. & Gekeler, F. 2010. Pathophysiology of cataract formation after vitrectomy. *Klin Monatsbl Augenheilkd.* **227**(3):175-80
- Moreschi, C.; Da Broi, U.; & Lanzetta, P. 2013. Medico-legal implications of traumatic cataract. *J. Forensic Legal Med.*, **20**(2):69-73
- Shah, M. A.; Shah, S. M.; Shah, S. B.; Patel, C. G. & Patel, U. A. 2011. Morphology of traumatic cataract: does it play a role in final visual outcome? *B. M. J. Open.* **1** ( 1 ) : e 0 0 0 0 6 0 .
- Brini, A.; Porte, A. & Stoeckel, M. E. 1963. Resorption of necrotic lens material by a newly formed lens capsule in certain types of cataract. *Nature.***200**:796-7.
- Neumayer, T.; Hirschschall, N.; Georgopoulos, M. & Findl, O. 2017. Natural course of posterior subcapsular cataract over a short time period. *Curr Eye Res.*,**2**(12):1604-7.
- Bansal, A. & Fenerty, C. H. 2020. Spontaneous resolution of a rapidly Formed dense cataract following Nd: YAG laser peripheral Iridotomy in a case of Pigmentary Glaucoma. *J Glaucoma.* **29** ( 4 ) : 3 2 2 - 5 .
- Matalia, J.; Kasturi, N.; Anaspure, H.; Shetty, B. K. & Matalia, H. 2015. Isolated posterior capsular split limited by Weiger's ligament after blunt ocular trauma in a child mimicking posterior *lenticonus*. *J A A P O S .* **19** ( 6 ) : 5 5 7 - 8 .
- Lee, S. I. & Song, H. C. 2001. A case of isolated posterior capsule rupture and traumatic cataract caused by blunt ocular trauma. *Korean J Ophthalmol.***15**(2):140-4.
- Wolter, J. R. 1963. Coup-contrecoup mechanism of ocularinjuries. *Am Ophthalmol.* **56**:785-96
- Khokhar, S. K.; Pillay, G.; Dhull, C. Agarwal, E.; Mahabir, M. & Aggarwal P. 2017. Pediatric cataract. *Indian J. Ophthalmol.*; **65** ( 1 2 ) : 1 3 4 0 - 9 .
- Medina, A. 2018. Prevention of myopia by partial correction of hyperopia: a twins study. *Int Ophthalmol.* **38** ( 2 ) : 5 7 7 - 8 3 .

Khatry, S. K.; Lewis, A. E. & Schein, O. D.  
2004. The epidemiology of ocular trauma  
in rural Nepal. *Br. J. Ophthalmol.*;  
8 ( 8 ) : 4 5 6 – 6 0 .

[PMC free article] [PubMed] [Google Scholar].

Alfaro, D.Ja.; Jablon, E. P. & Rodriguez, F. M.  
2005. Fishing-related ocular trauma. *Am. J.  
Ophthalmol.*, 139 : 4 8 8 – 9 2 .

## المخلص

وصل طفل يبلغ من العمر عشر سنوات إلى عيادة طب العيون في مستشفى الوحدة التعليمي في درنة كحالة طارئة، مصابًا بجرح في عينه اليمنى نتيجة تناول الطعام بالملعقة عن طريق الخطأ من أخته، وذلك لتقييم احتمال وجود جرح مفتوح في مقلة العين وتحديد العلاج المناسب. اشتكى الطفل من ألم شديد، فنقل إلى مركز الطوارئ المحلي لإجراء الفحوصات اللازمة. لم يكشف فحص المصباح الشقي عن وجود جسم غريب. في صباح اليوم التالي، استيقظ الطفل وهو يعاني من ألم متزايد. عند فحصه من قبل طبيب العيون، لاحظ وجود تمزق صغير في القرنية يتراوح طوله بين 2 و 3 ملم عند موضع الساعة 8 أو 9، بالإضافة إلى تغير في عدسة العين (إعتام عدسة العين). أظهرت النتائج عدم وجود أي إصابة أو جراحة أو مرض سابق في العين. كما كان المريض مصابًا بشلل دماغي. وقد شفي الطفل تلقائيًا خلال ستة أشهر. يُعد علاج إعتام عدسة العين الرضحي لدى الأطفال، والإدارة التحفظية مع الحفاظ على عدسة العين، أمرًا بالغ الأهمية لمرضى إعتام عدسة العين الرضحي الصغار، بدلًا من التدخل الجراحي.

**الكلمات المفتاحية:** عيادة طب العيون، إصابة العين اليمنى، الشلل الدماغي.

